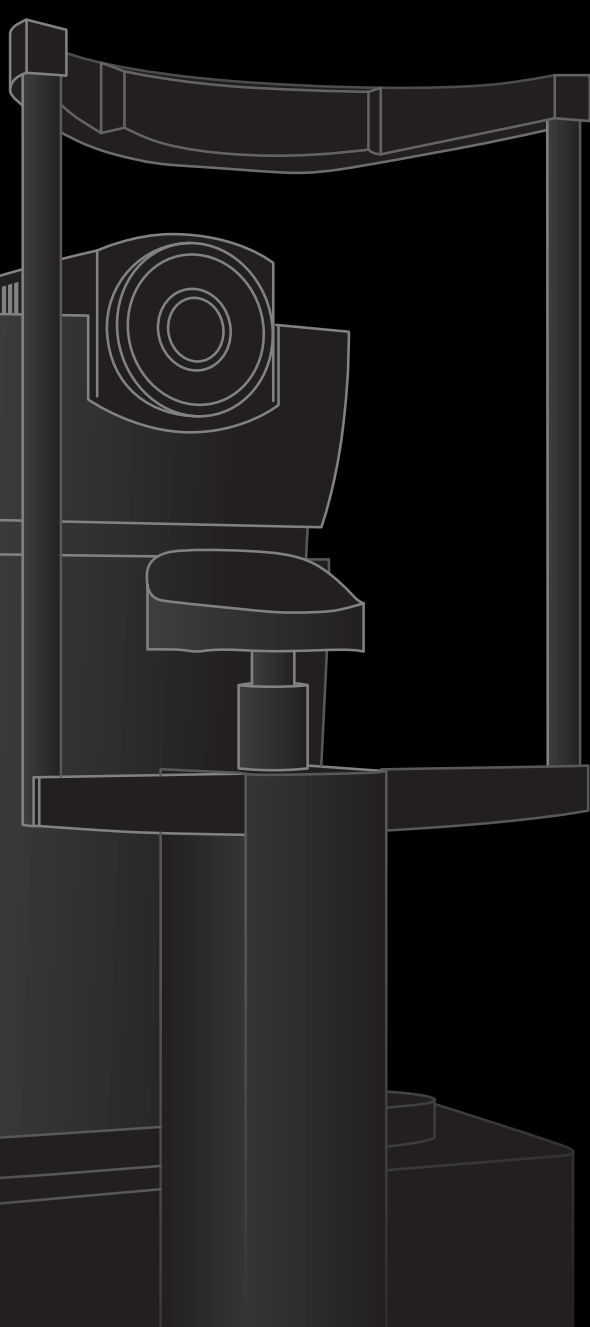

ANTERION[®]

Multimodal Imaging Platform
Optimized for the Anterior Segment

■ HEIDELBERG
ENGINEERING ■

The multimodal functionality you need

The image quality you expect

Imaging App

- Anterior chamber and angle imaging
- Corneal and scleral imaging
- Visualization of the lens and both surfaces
- Customizable scan patterns
- Peripheral imaging

The expandable design you want (optional)

Cornea App

- Corneal topography
- Corneal tomography
- Pachymetry
- Total corneal power
- Corneal wavefront analysis
- Corneal differential maps
- Progression analysis

Cataract App

- Axial length
- Lens thickness
- Aqueous depth
- Central corneal thickness
- Anterior axial curvature
- Total corneal power
- Total corneal wavefront
- Spheric and toric IOL calculator
- Formulas:
 - SRK/T
 - Haigis, Haigis L
 - Holladay I
 - Barrett formulas (Universal II, Toric, True-K, True-K Toric)
- ULIB import
- IOL CON import
- Okulix interface

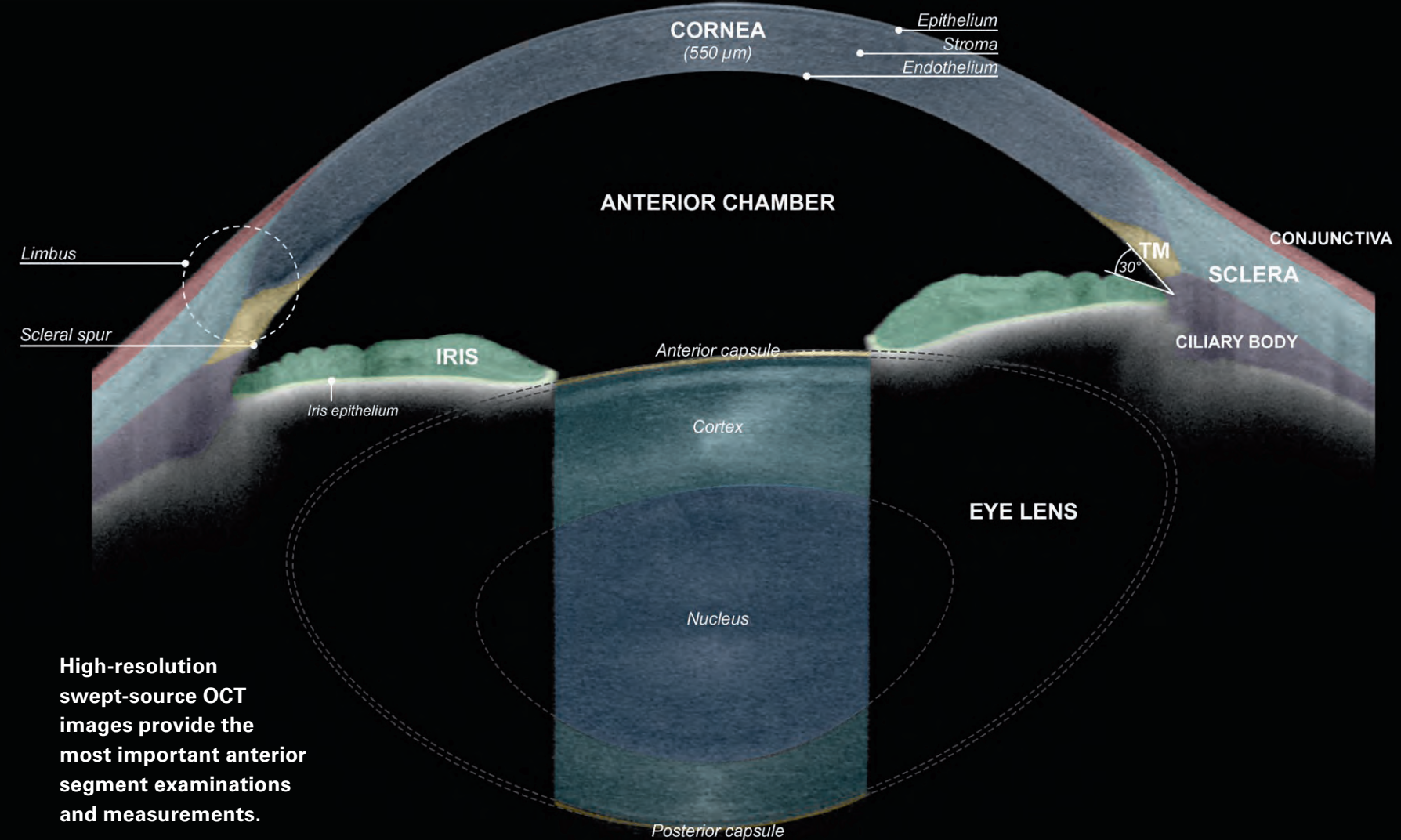
Metrics App

- Anterior chamber angle assessment
- 360° graphs of angle parameters
- Anterior chamber volume
- Lens vault
- Lens thickness
- Free-hand measurements

Experience confident diagnostics and workflow optimization

- Visually confirm all measurements with exceptionally clear swept-source OCT images.
- Increase efficiency and save space with a customizable, compact platform that meets your individual needs.
- Simplify the patient journey and transform your clinical workflow.
- Discover the speed and security of HEIDELBERG EYE EXPLORER HEYEX 2 image management.

Anterior segment anatomy

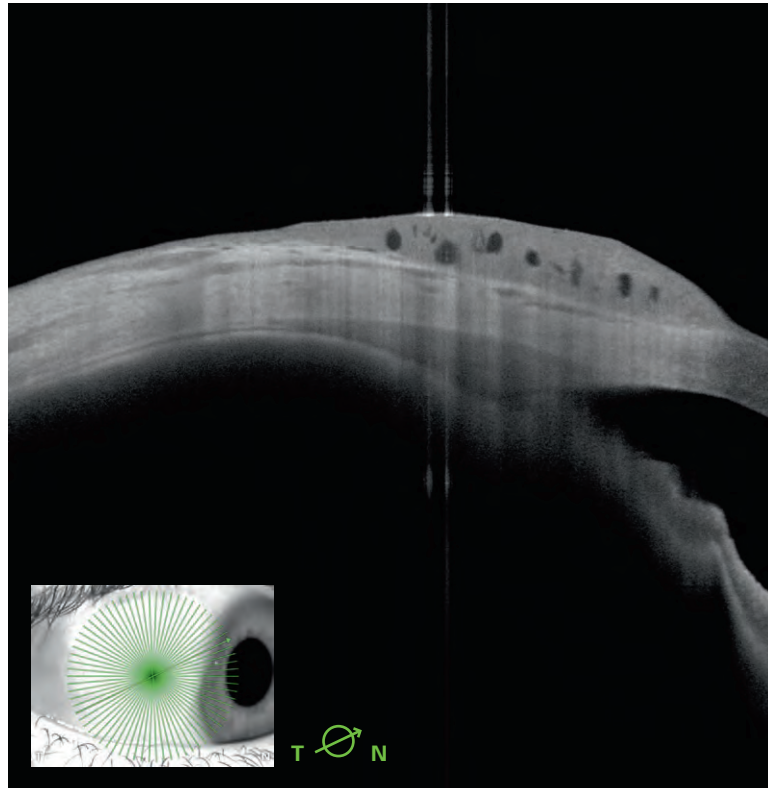


High-resolution swept-source OCT images provide the most important anterior segment examinations and measurements.

Imaging App – Enhance your clinical confidence

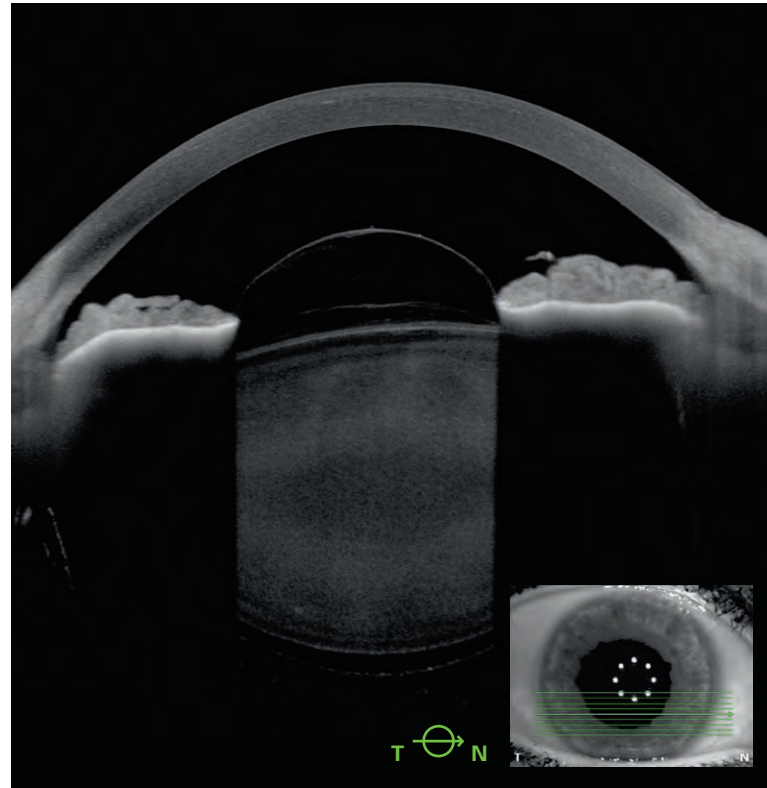
The Imaging App comes as standard. Visualize various anterior segment pathologies or surgical results, such as keratoplasty, implanted IOLs, and corneal rings.

A detailed visualization of the sclera, ciliary body, and rectus muscle assists you in the diagnosis and management of pathologies that impact these anatomical structures.

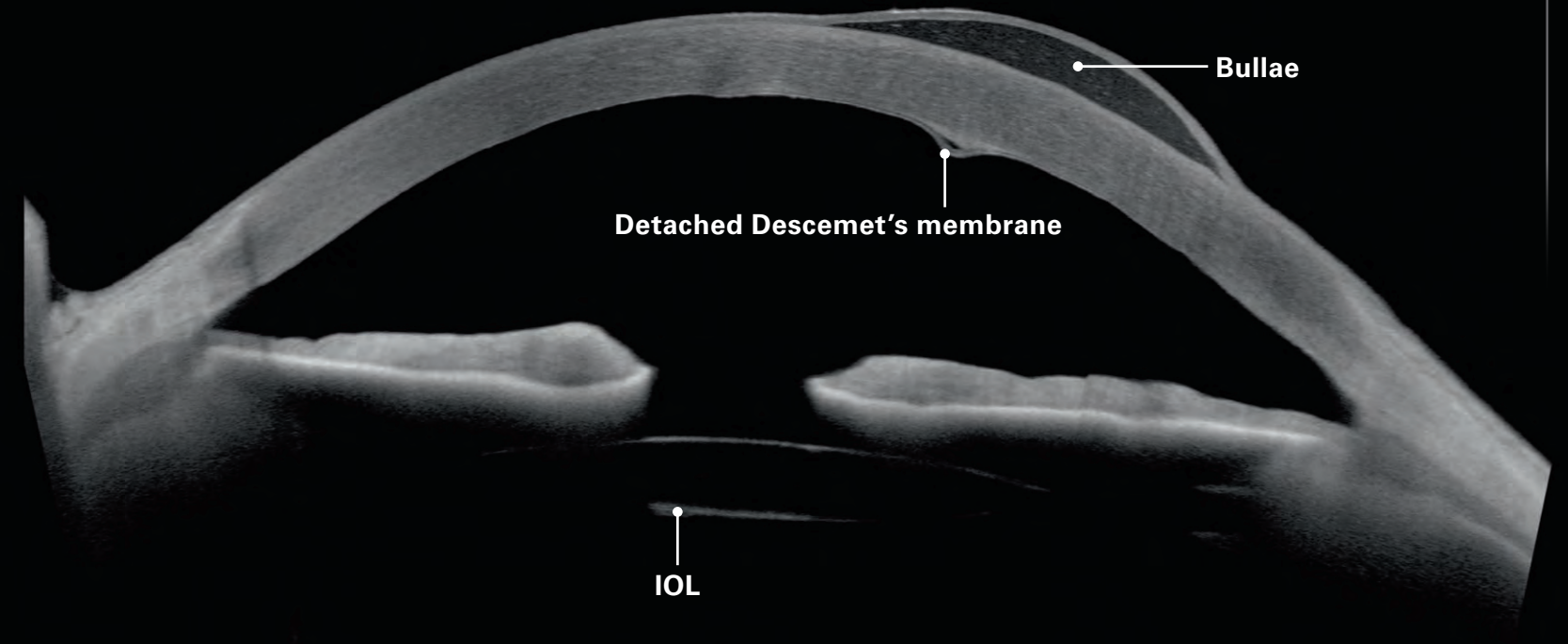


Conjunctival nevus (lateral fixation)

Image courtesy: Sacha Nahon-Esteve, MD, Nice, France

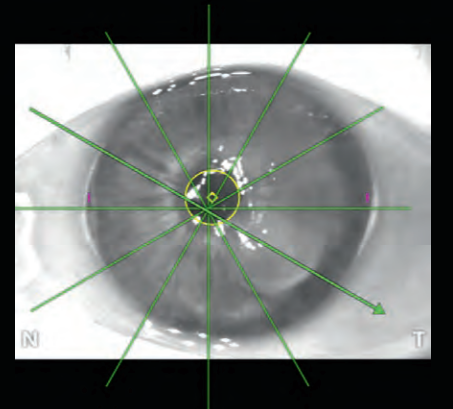


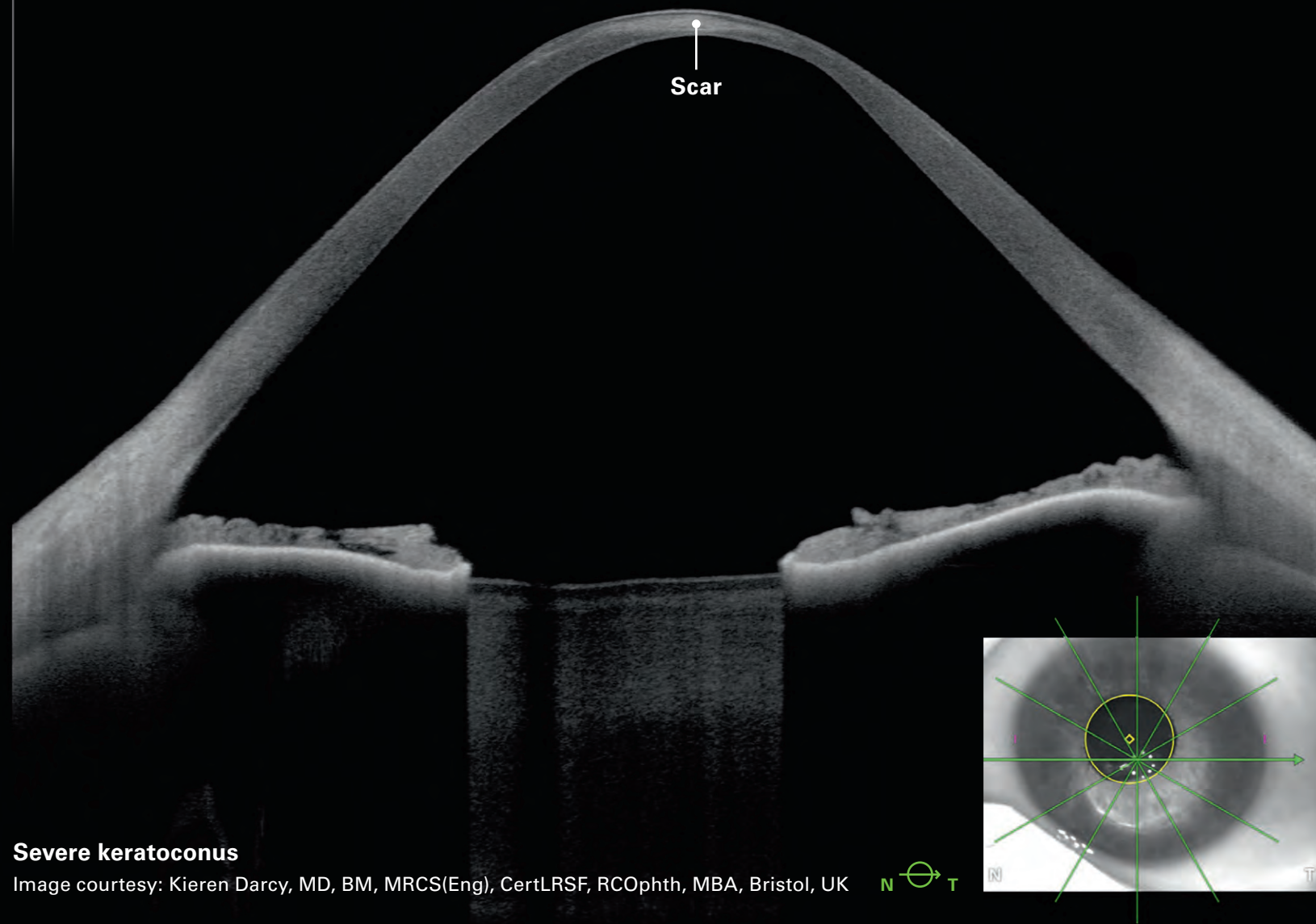
Post trauma, vitreous in the anterior chamber



Bullae due to hydrops

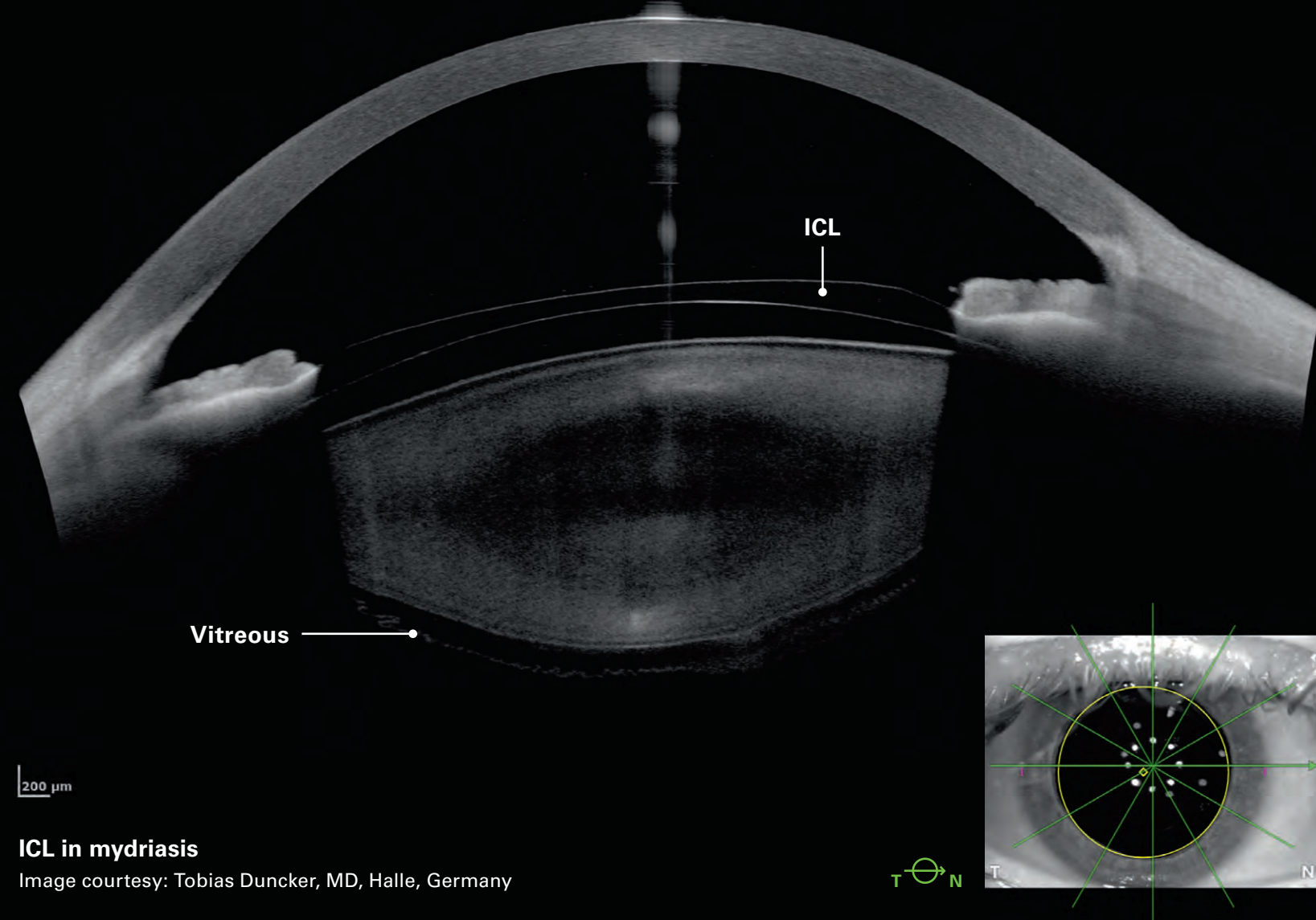
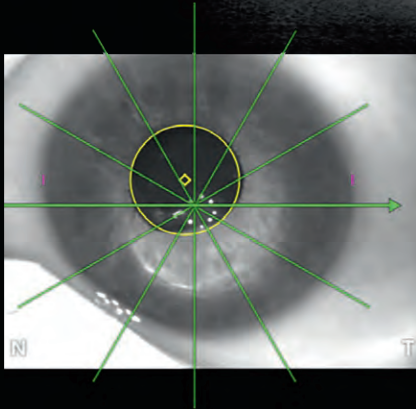
Image courtesy: Kieren Darcy, MD, BM, MRCS(Eng), CertLRSF, RCOphth, MBA, Bristol, UK





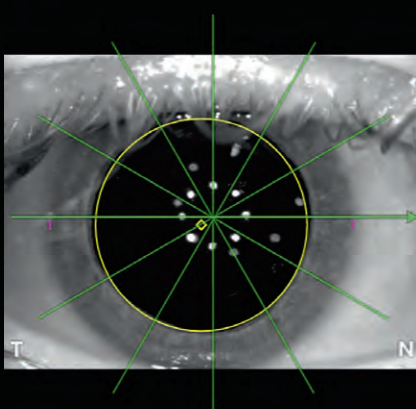
Severe keratoconus

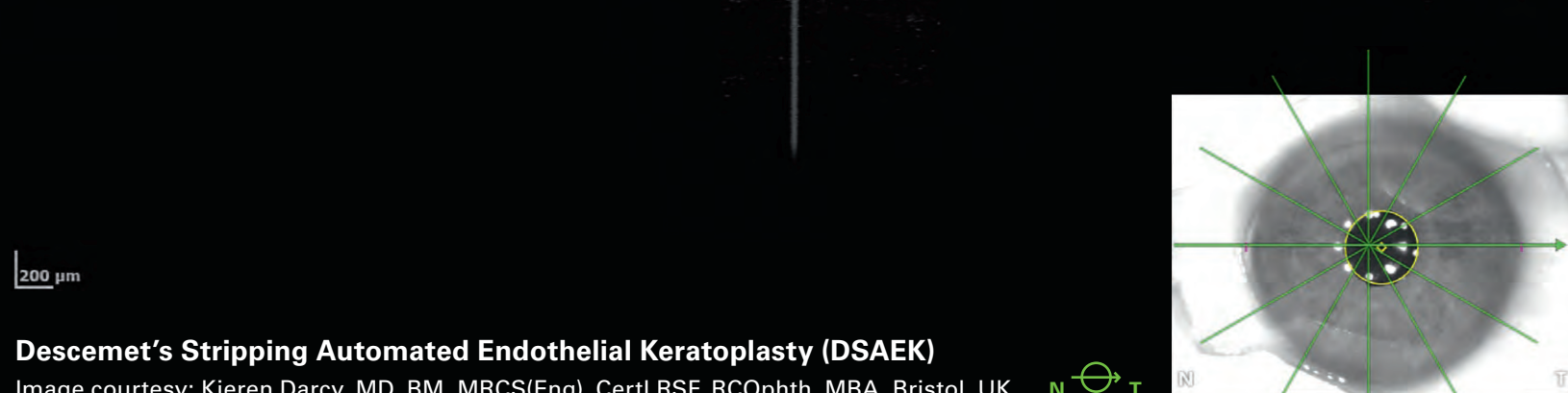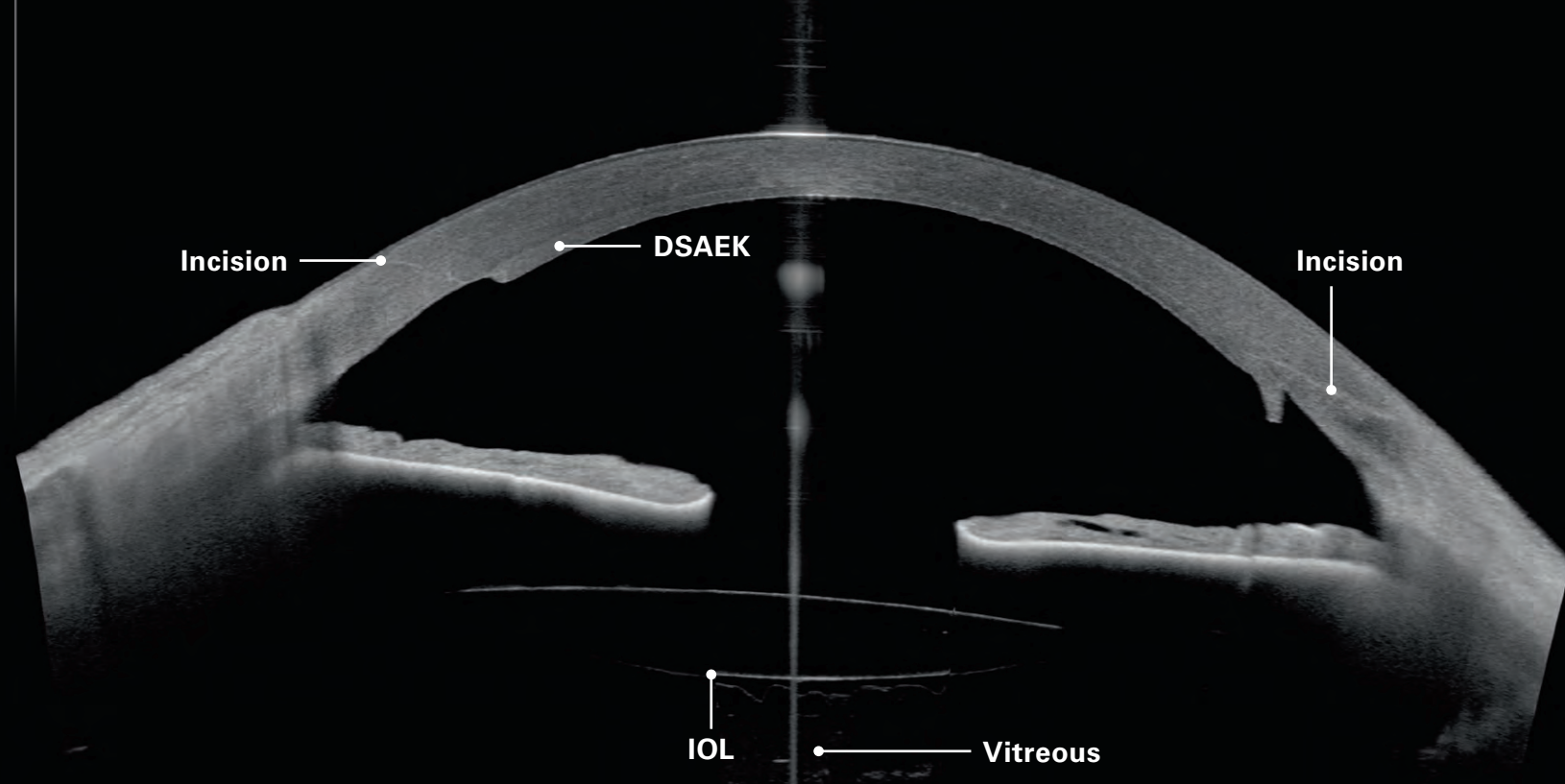
Image courtesy: Kieren Darcy, MD, BM, MRCS(Eng), CertLRSF, RCOphth, MBA, Bristol, UK



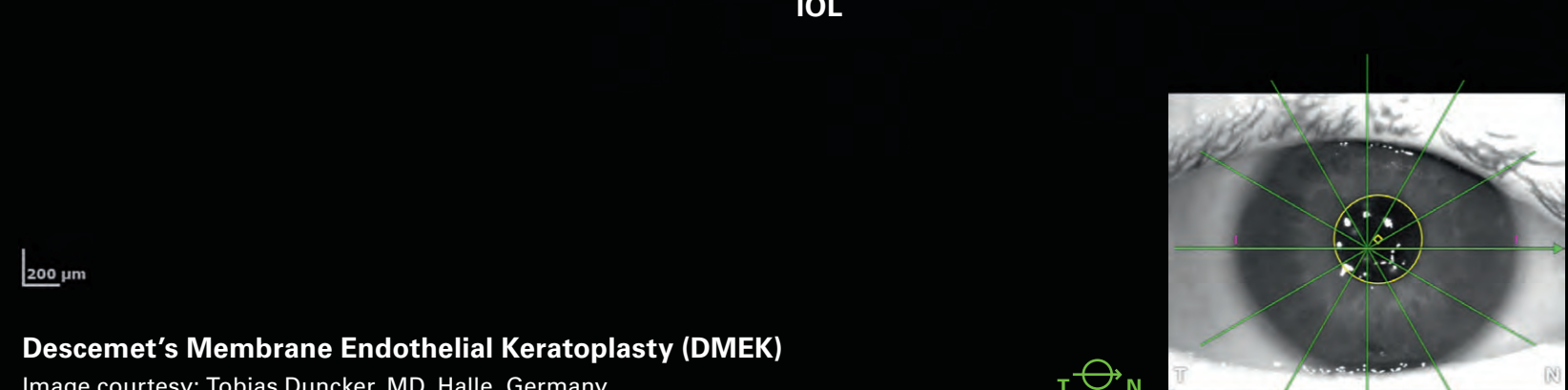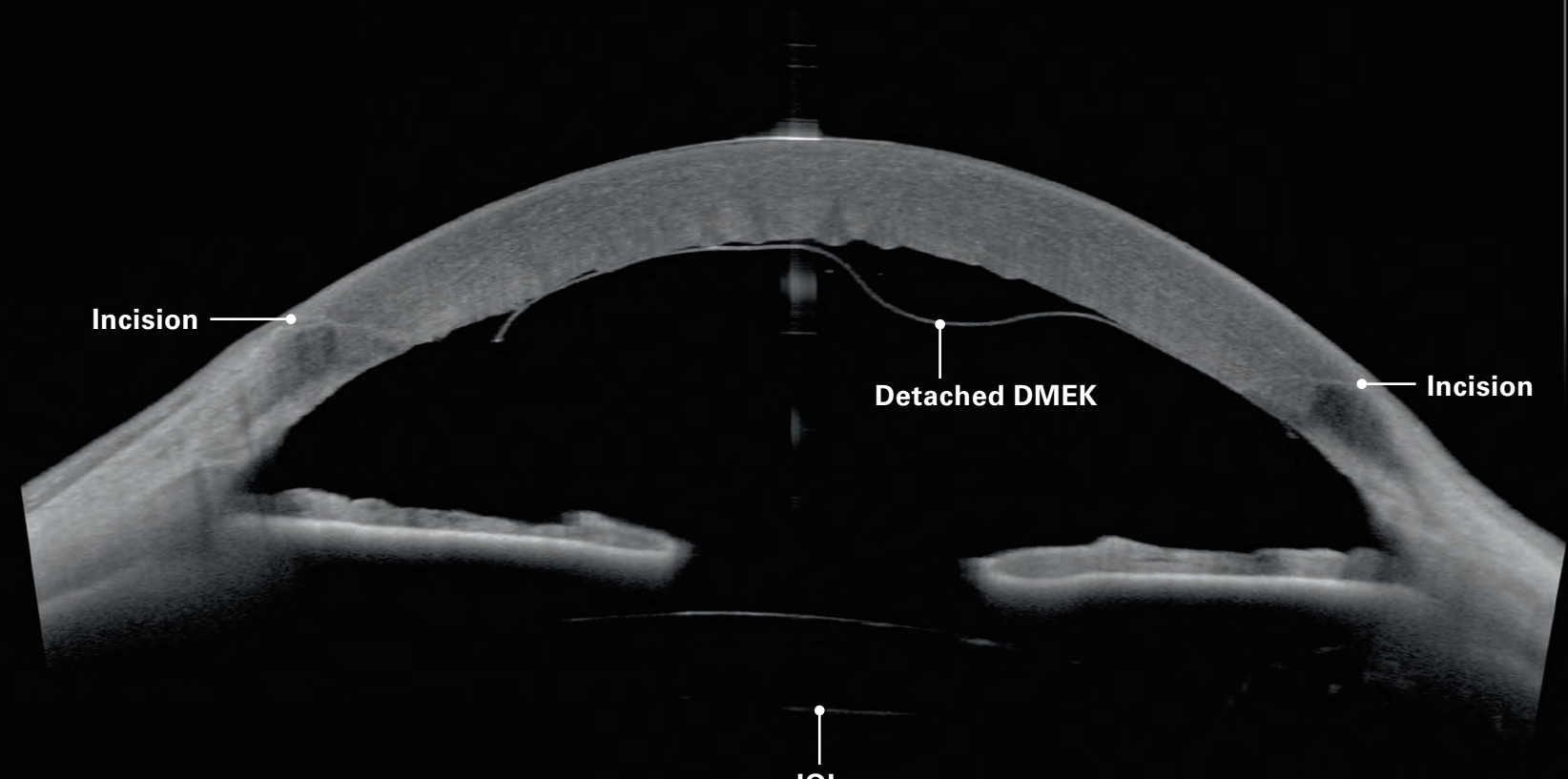
ICL in mydriasis

Image courtesy: Tobias Duncker, MD, Halle, Germany



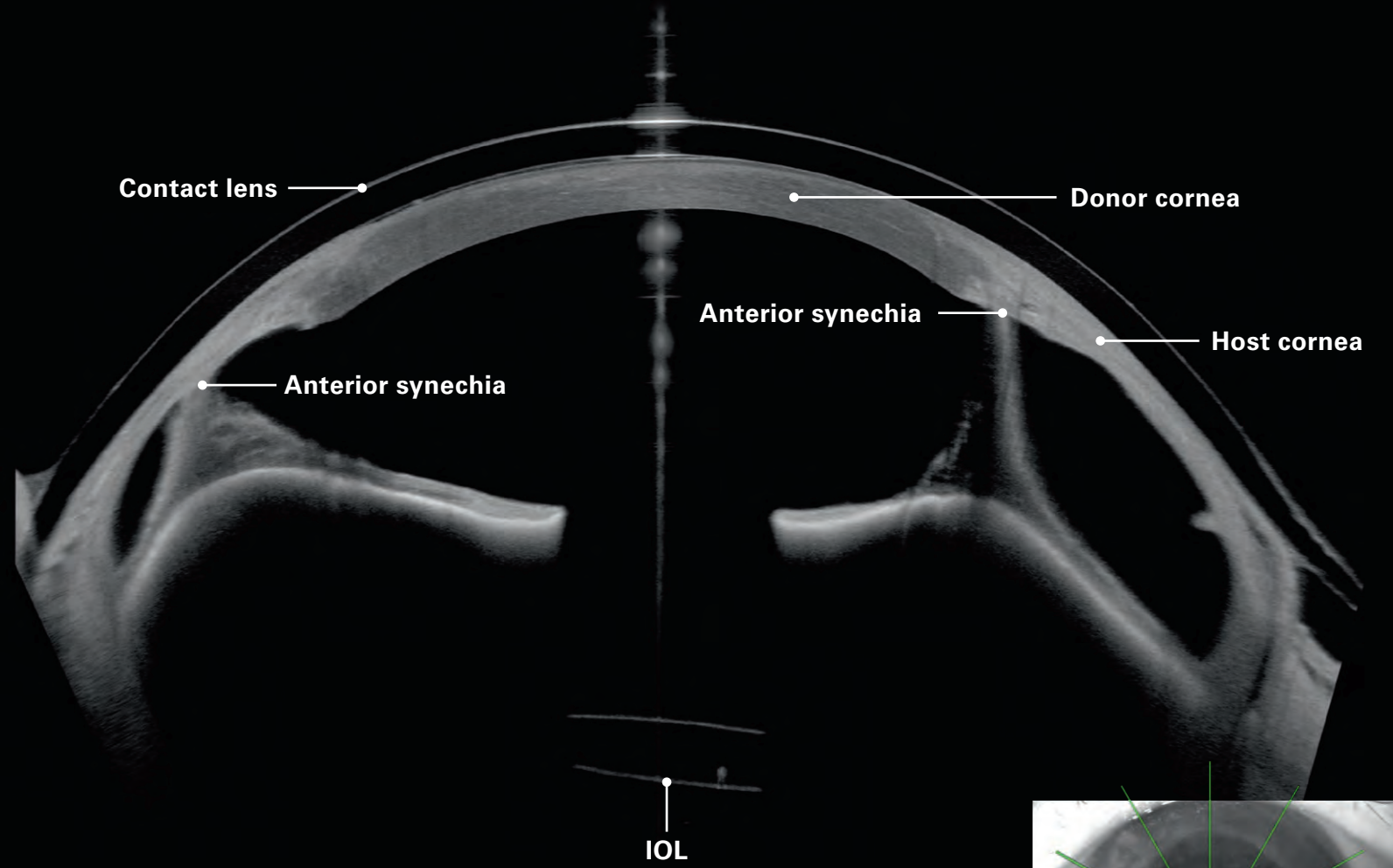


Descemet's Stripping Automated Endothelial Keratoplasty (DSAEK)
 Image courtesy: Kieren Darcy, MD, BM, MRCS(Eng), CertLRSF, RCOphth, MBA, Bristol, UK



Descemet's Membrane Endothelial Keratoplasty (DMEK)
 Image courtesy: Tobias Duncker, MD, Halle, Germany

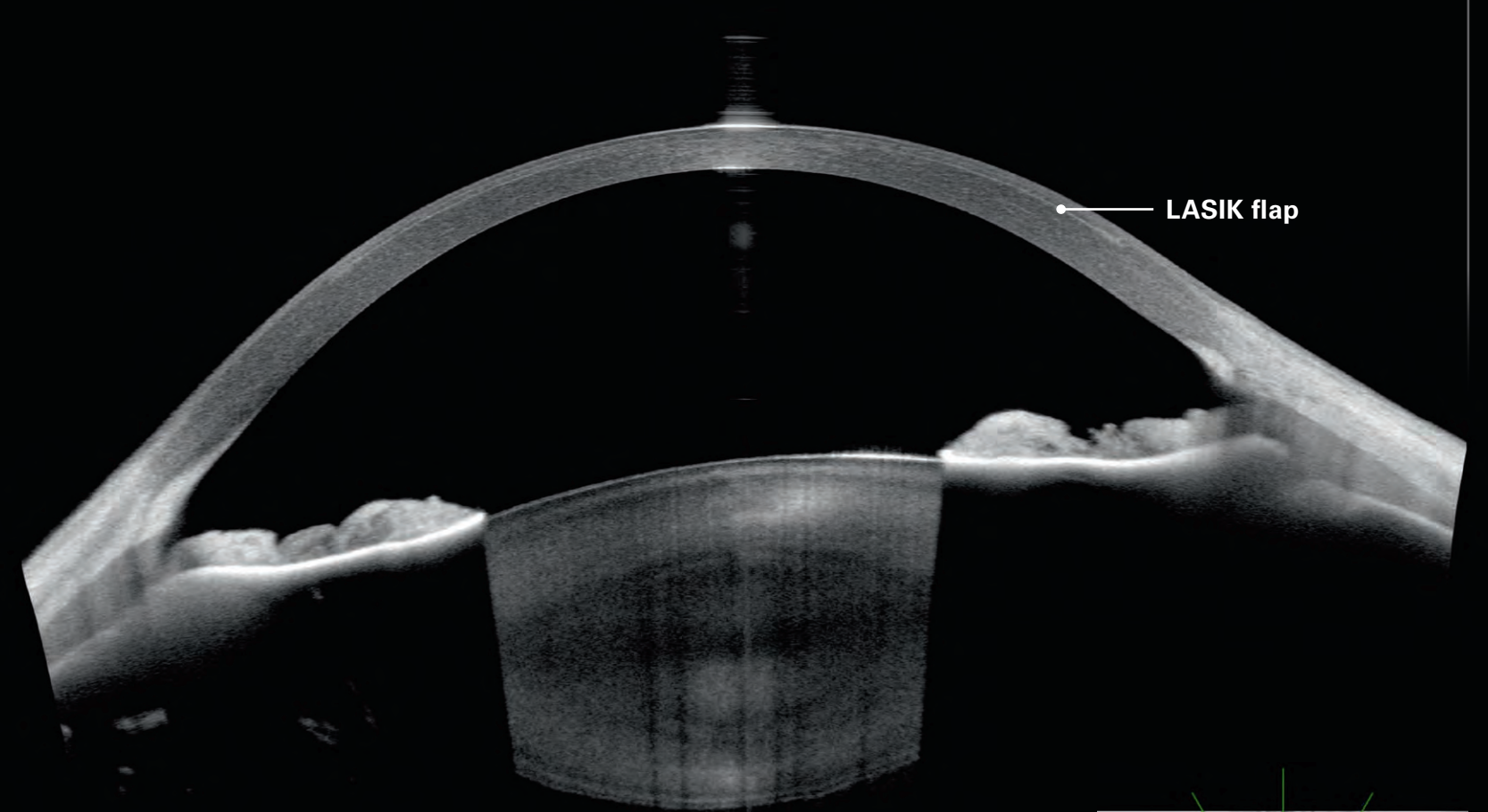
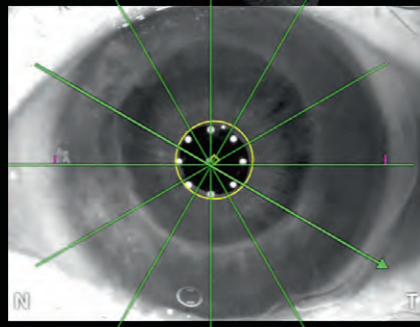




200 μm

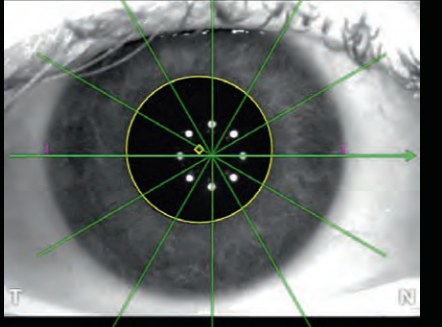
Keratoplasty, anterior synechia, pseudophakic eye with contact lens

Image courtesy: Tobias Duncker, MD, Halle, Germany



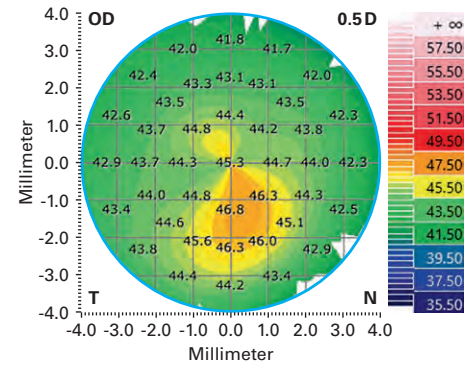
200 μm

LASIK

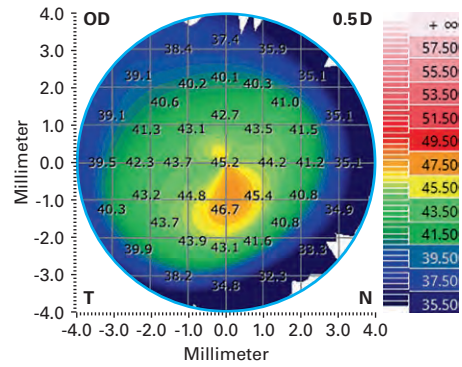


Cornea App – Customized reports enhance your workflow

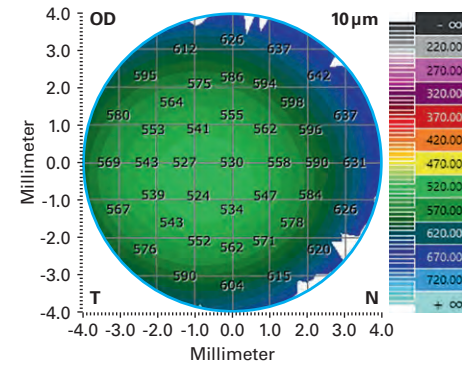
Anterior axial curvature



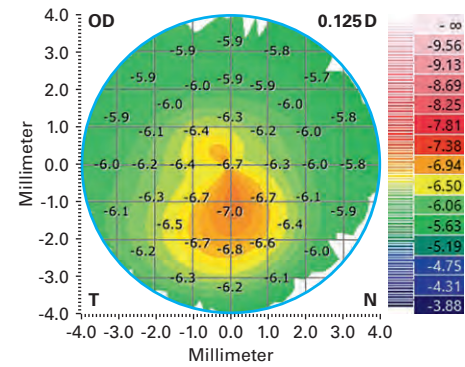
Anterior tangential curvature



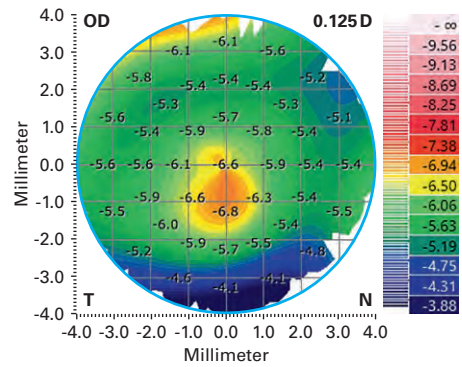
Pachymetry



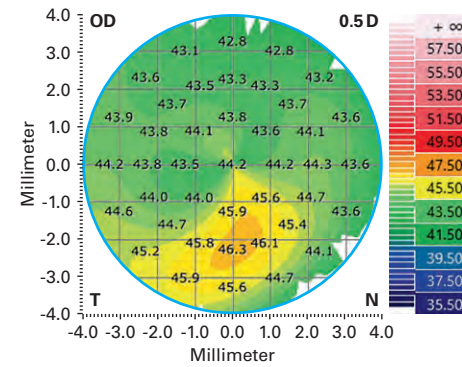
Posterior axial curvature



Posterior tangential curvature



Total corneal power

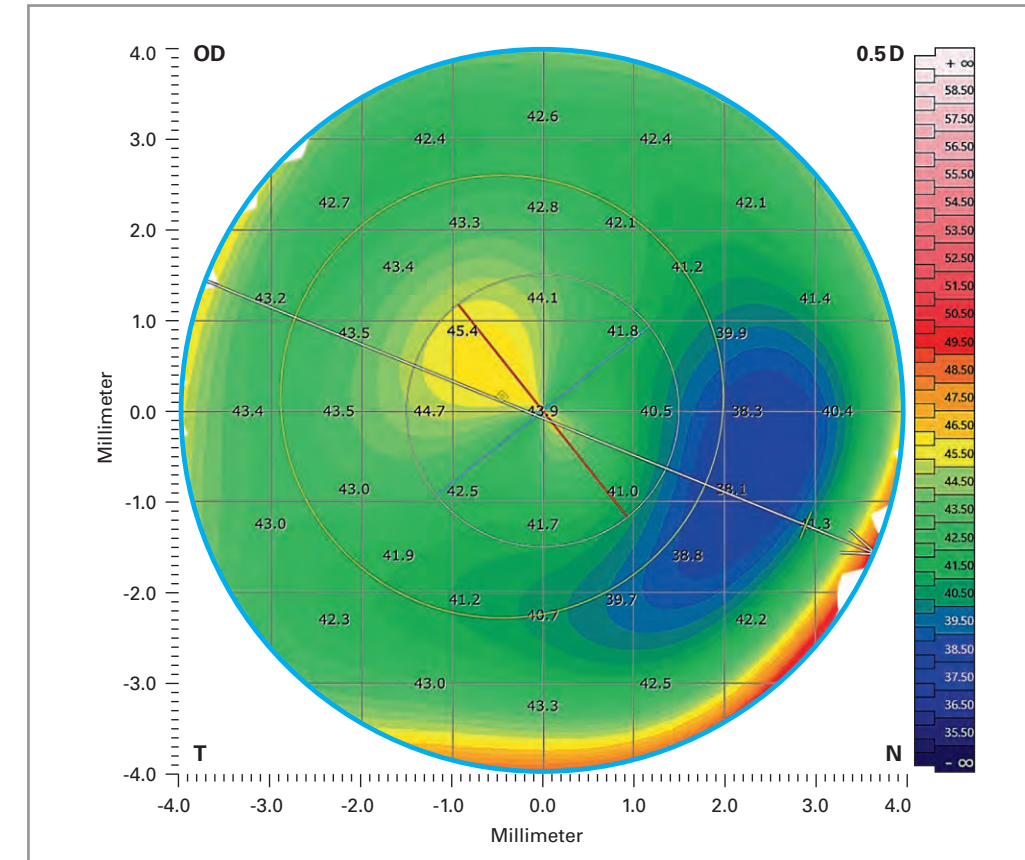


Keratoconus Multiview

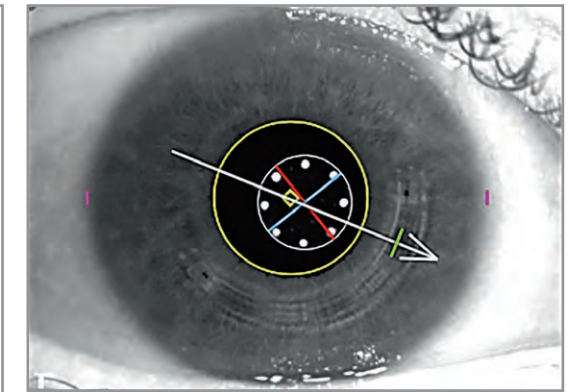
Image courtesy: Oliver Findl, MD, MBA, FEBO, Vienna, Austria

Corneal maps correlate with camera and OCT images

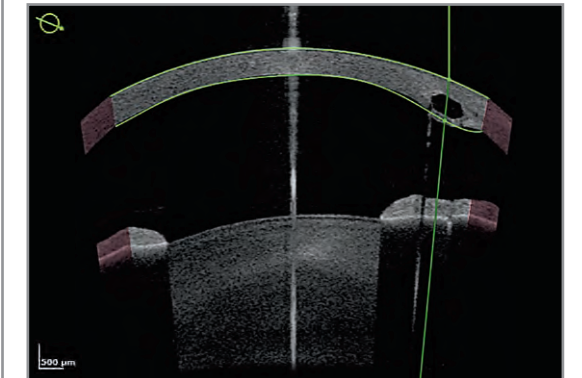
Total corneal power map



IR camera image



OCT cross-sectional scan

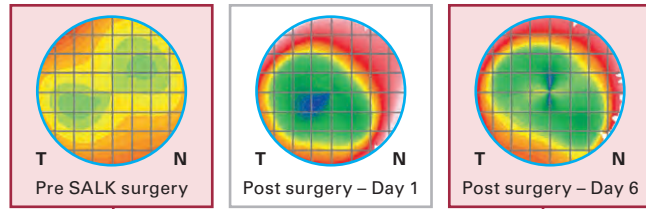


Intrastromal corneal ring segment

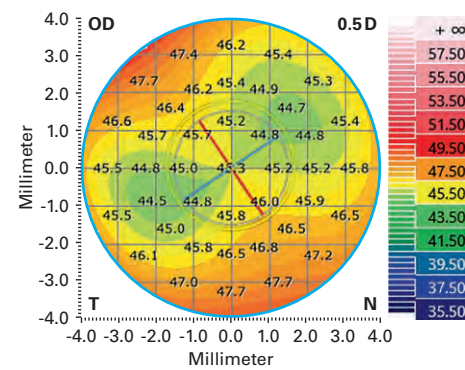
Image courtesy: Oliver Findl, MD, MBA, FEBO, Vienna, Austria

Visualize, measure and document progression

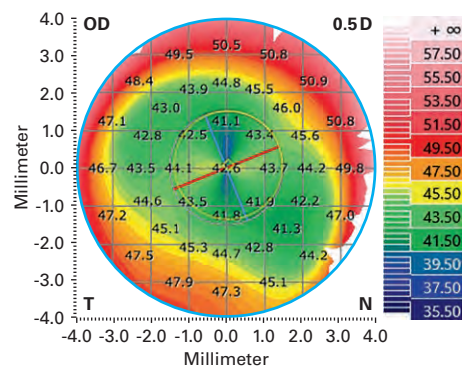
Examinations –
Total corneal
power map:



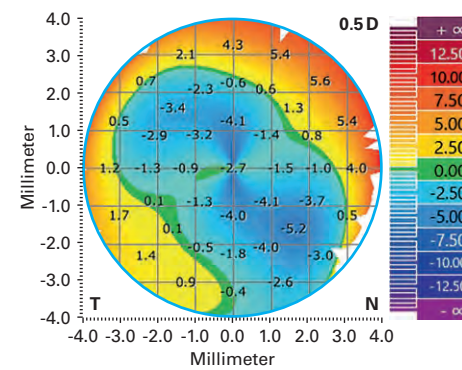
Baseline Pre SALK surgery



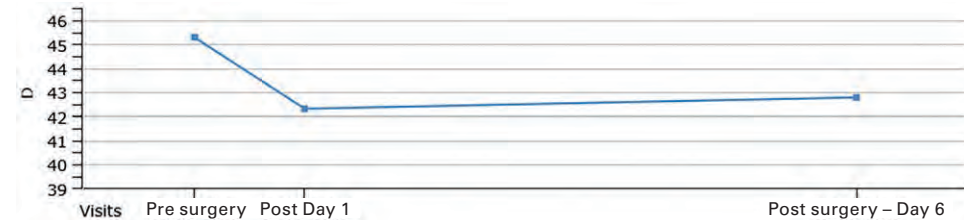
Follow-up Post surgery – Day 6



Follow-up – Baseline Difference



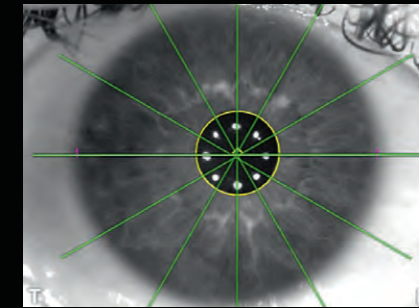
Trend analysis Total corneal power – K (average)



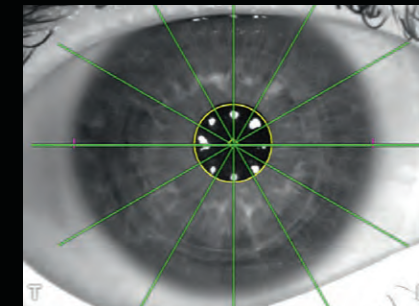
Superficial Anterior Lamellar Keratoplasty – SALK

Image courtesy: Kieren Darcy, MD, BM, MRCS(Eng), CertLRSF, RCOphth, MBA, Bristol, UK

Baseline – Pre SALK surgery

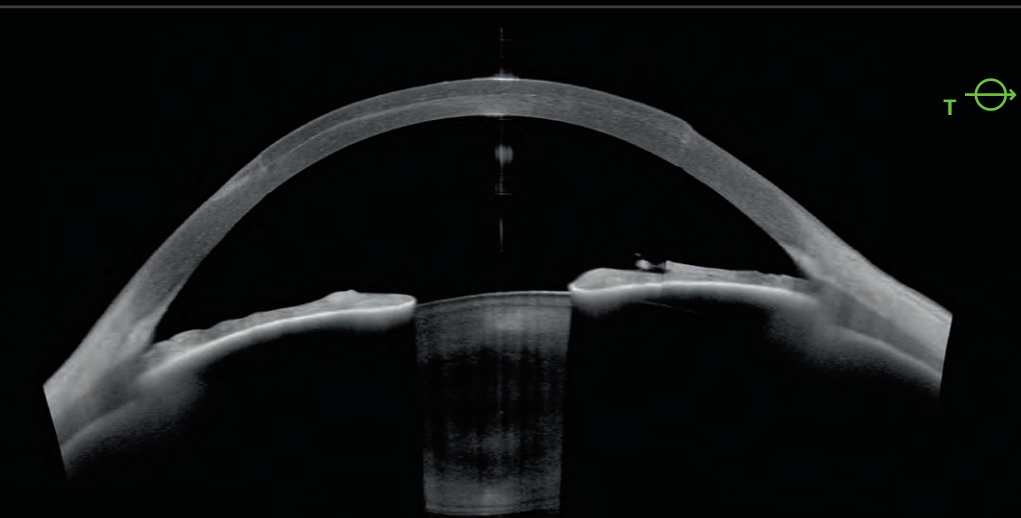
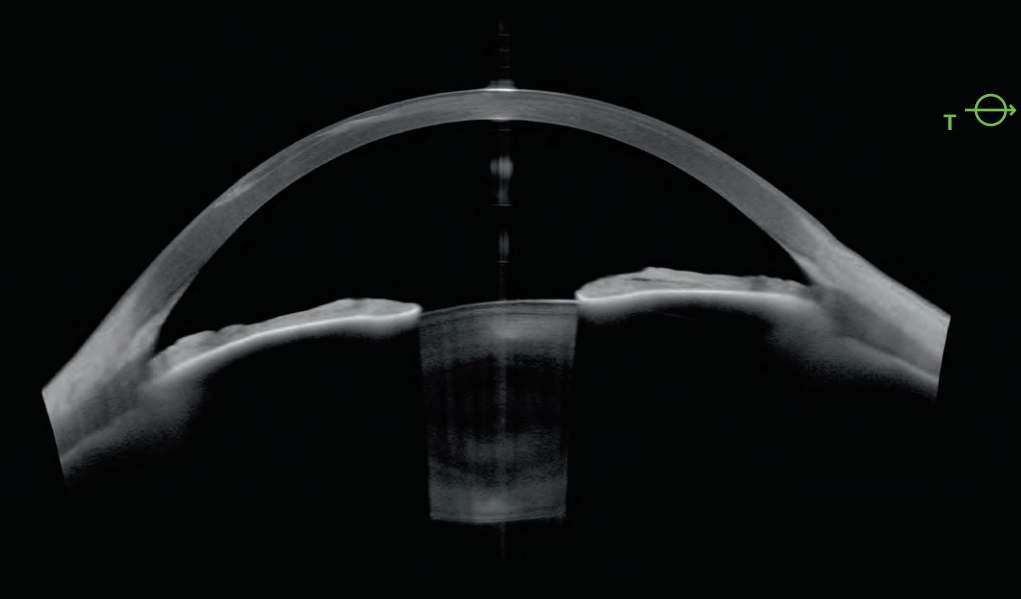


Follow-up – Day 6 –
Post SALK surgery



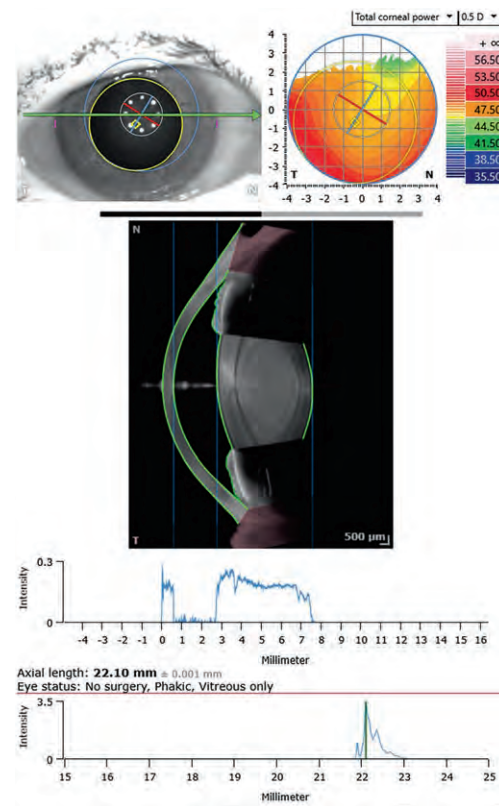
Confirm the reliability of your data using the Imaging App if clinically indicated

Image courtesy: Kieren Darcy, MD, BM, MRCS(Eng), CertLRSF, RCOphth, MBA, Bristol, UK

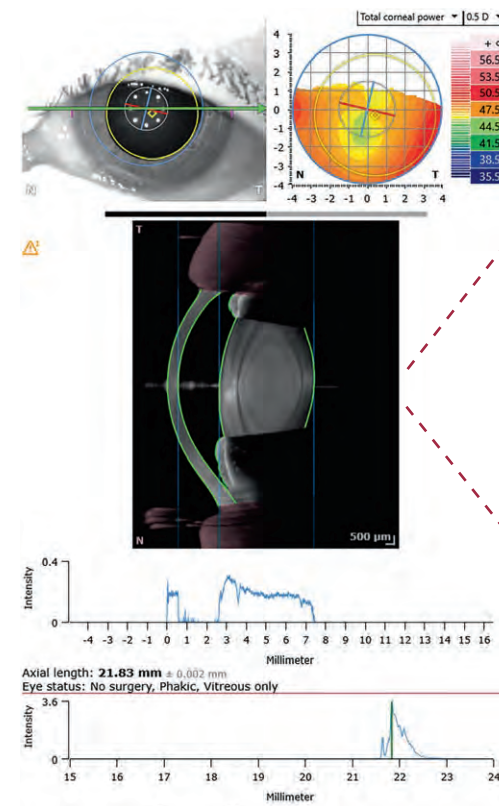


Cataract App – Confirm biometry on OCT images

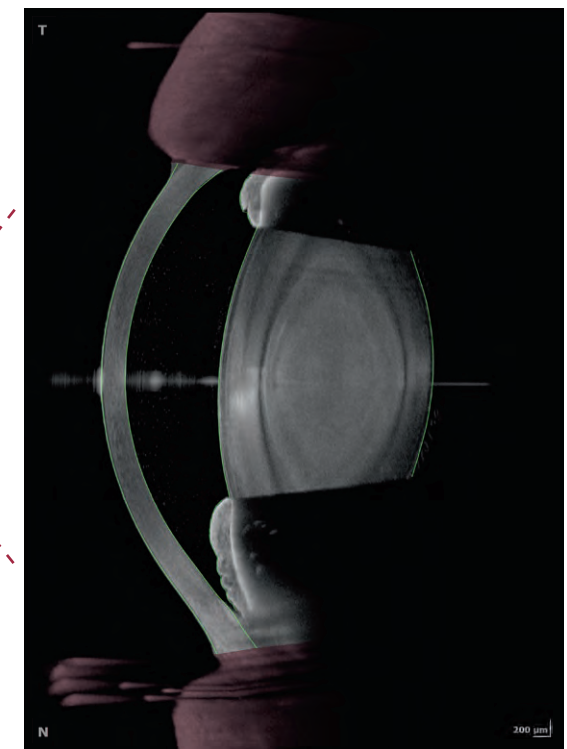
Biometry OD



Biometry OS



OCT cross-sectional scan OS



Conveniently compare the biometry data of both eyes. Optimize your clinical workflow using OCT images to visually confirm your biometry data. See what you measure and measure what you see – for more confidence.

Save time and streamline your workflow

Parameter tab

	OD	OS	OD - OS Difference
Anterior axial curvature (simulated)			
nk = 1.3375; 3 mm ring			
SimK average	47.17 D	46.47 D	0.70 D
SimK (steep)	47.40 D @ 134°	47.14 D @ 164°	
SimK (flat)	46.93 D @ 44°	45.82 D @ 74°	
Astigmatism (steep)	0.47 D @ 134°	1.32 D @ 164°	
Astigmatism (Steep)			
nc = 1.376; nah=1.336; 3 mm ring			
Astigm. (total)	0.57 D @ 148°	1.82 D @ 167°	
Astigm. (posterior)	-0.30 D @ 91°	-0.35 D @ 91°	
Δ Ast. (anterior - total)	-0.11 D @ -14°	-0.49 D @ -3°	
Total corneal wavefront			
3 mm zone, pupil-centered			
Z ² Spherical aberration	0.03 μm	n/a	n/a
RMS HOA	0.12 μm	n/a μm	n/a μm
Pachymetry			
CCT (vertex)	564 μm	534 μm	30 μm
Anterior segment			
AQD	2.18 mm	2.07 mm	0.11 mm
WTW	11.22 mm	11.15 mm	
Lens thickness	4.79 mm	4.78 mm	0.01 mm
Pupil			
Pupil diameter	6.5 mm	6.4 mm	0.1 mm
Pupil center x/y (kappa)	-0.39/-0.69 mm	0.42/-0.31 mm	
Axial length			
Length	22.10±0.00 mm	21.83±0.00 mm	0.27 mm

Spheric calculator OS

Eye status: No surgery, Phakic, Vitreous only

Target refraction: 0.00 D IOL database: keyuser

Template: Custom

IOL power	Residual refraction
23.71 (optimal)	0.00 (optimal)
24.50	-0.57
24.00	-0.21
23.50	0.15
23.00	0.50
22.50	0.84

Toric calculator OS

Posterior astigmatism: Measured 0°

Incision location: 0°

Surgically induced astigmatism: 0.2 D

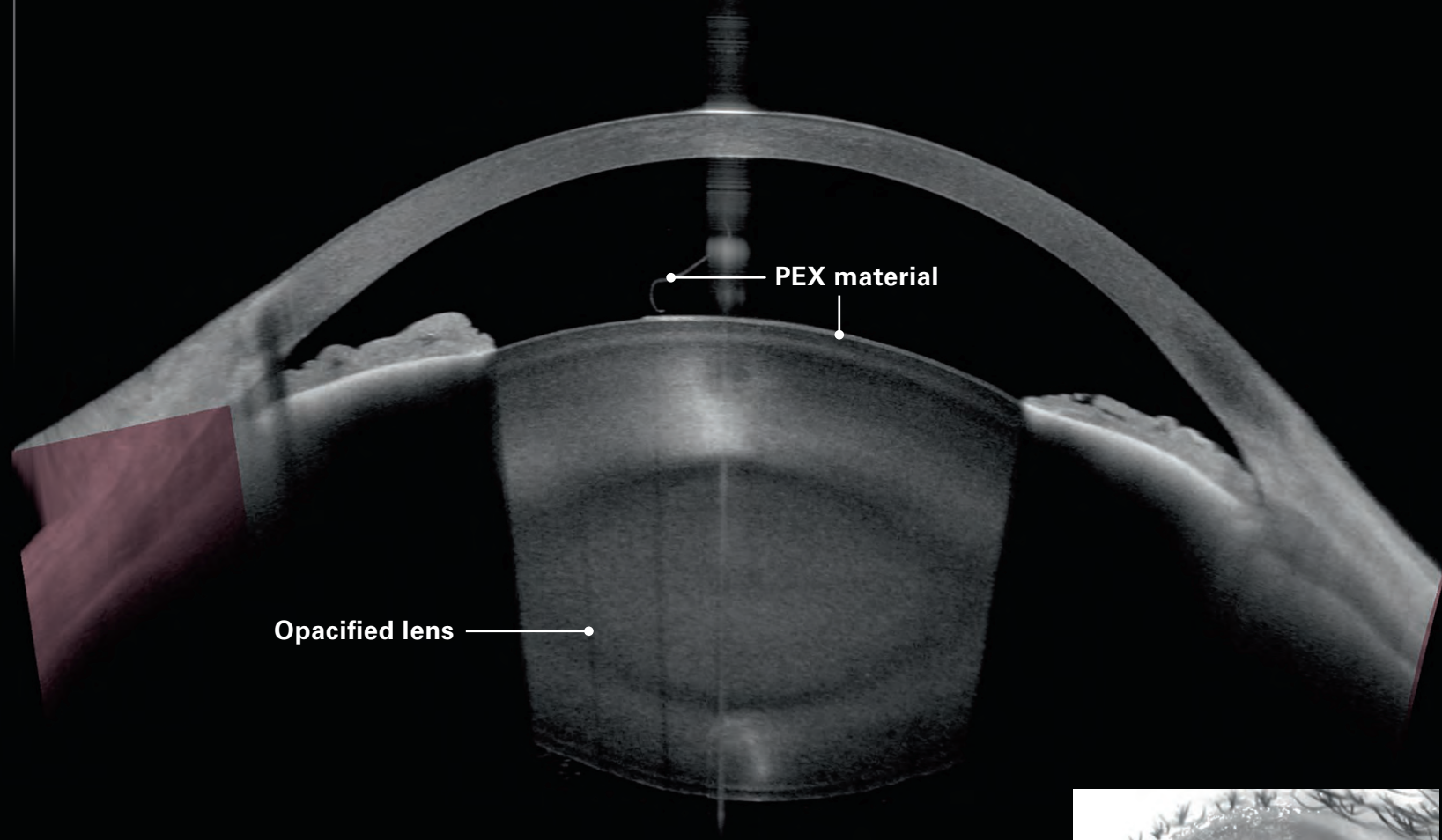
IOL axis: 166°

IOL overlay opacity: [Slider]

Toric calculator applies "Barrett Toric"

Toric IOL details			Residual astigmatism	
Cyl. IOL	Cyl. CP	Axis	Cylinder	Axis (Steep)
1.25 D	0.85 D	166°	0.69 D	166°
2.00 D	1.35 D	166°	0.18 D	166°
2.75 D	1.86 D	166°	0.32 D	76°

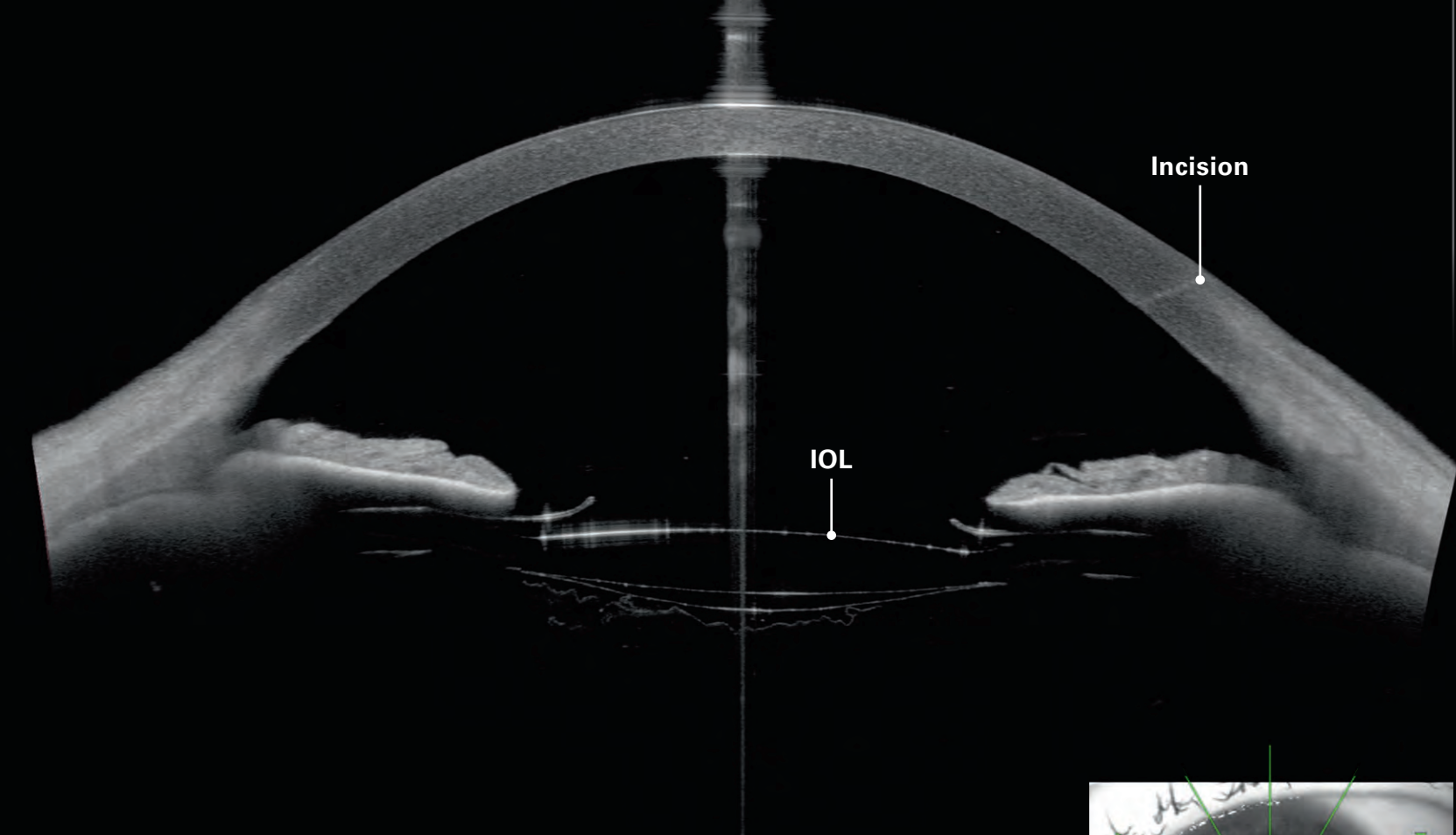
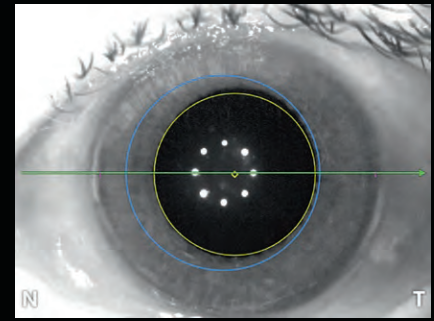
Using the dedicated parameter tab, you can easily identify differences between the right and left eye. The integrated spheric and toric IOL calculator adds further convenience to your pre-operative routine and streamlines your workflow.



200 μm

Nuclear 3+ cataract with pseudoexfoliation syndrome (PEX)

Image courtesy: Oliver Findl, MD, MBA, FEBO, Vienna, Austria

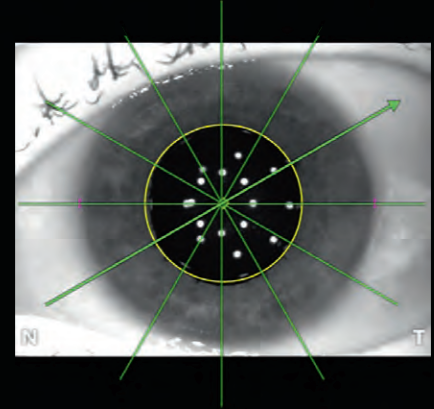


200 μm

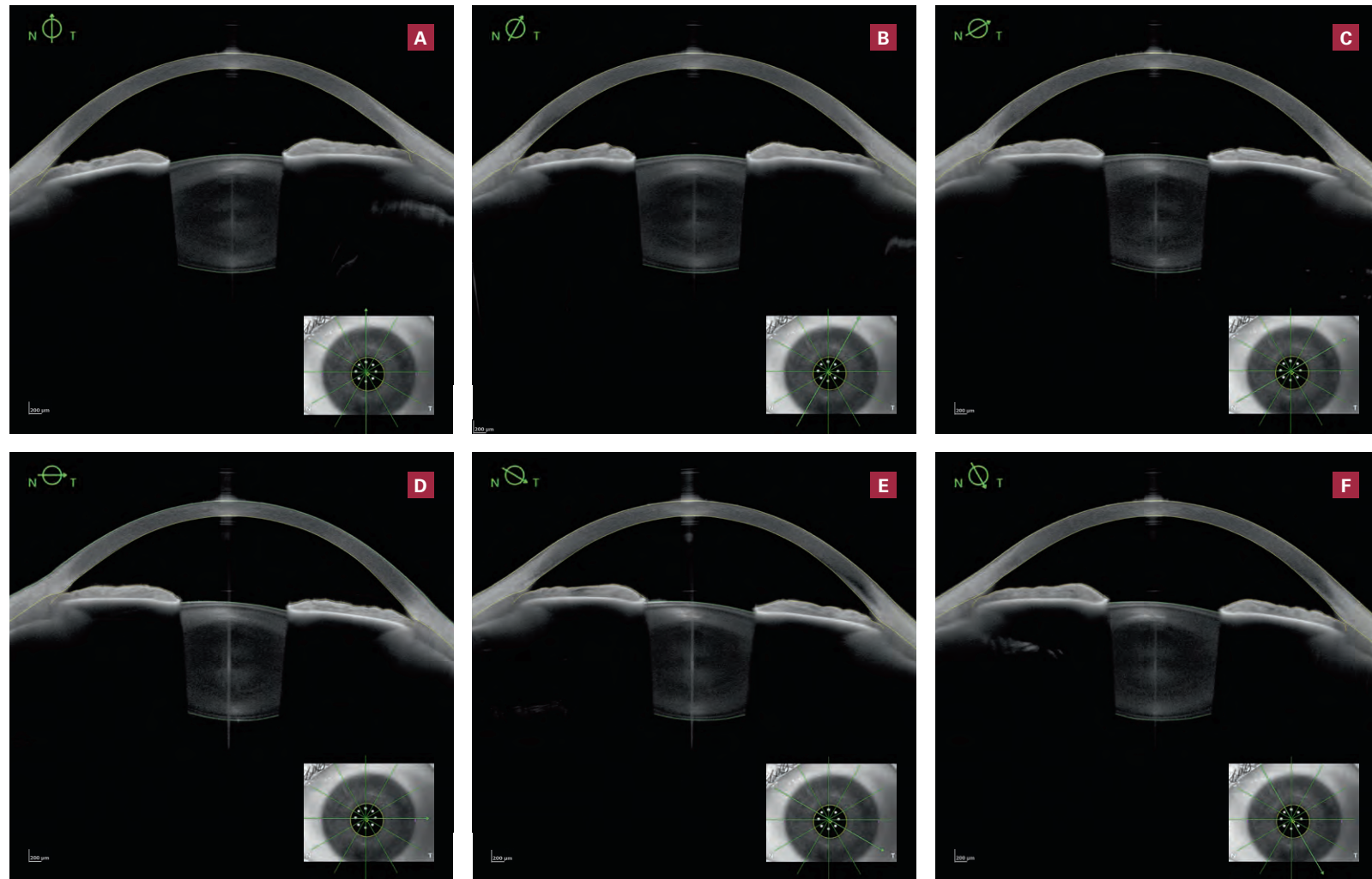
Dilated pseudophakic eye, post cataract and capsulotomy

Confirm the reliability of your data using the Imaging App if clinically indicated.

Image courtesy: Ulrich Kellner, MD, Siegburg, Germany

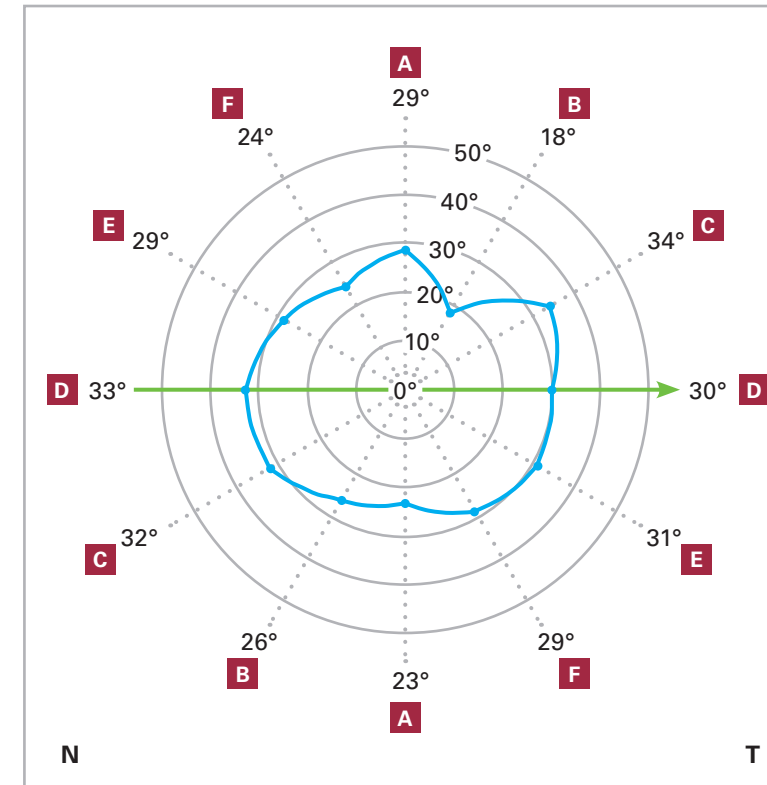


Metrics App – Measure what you see

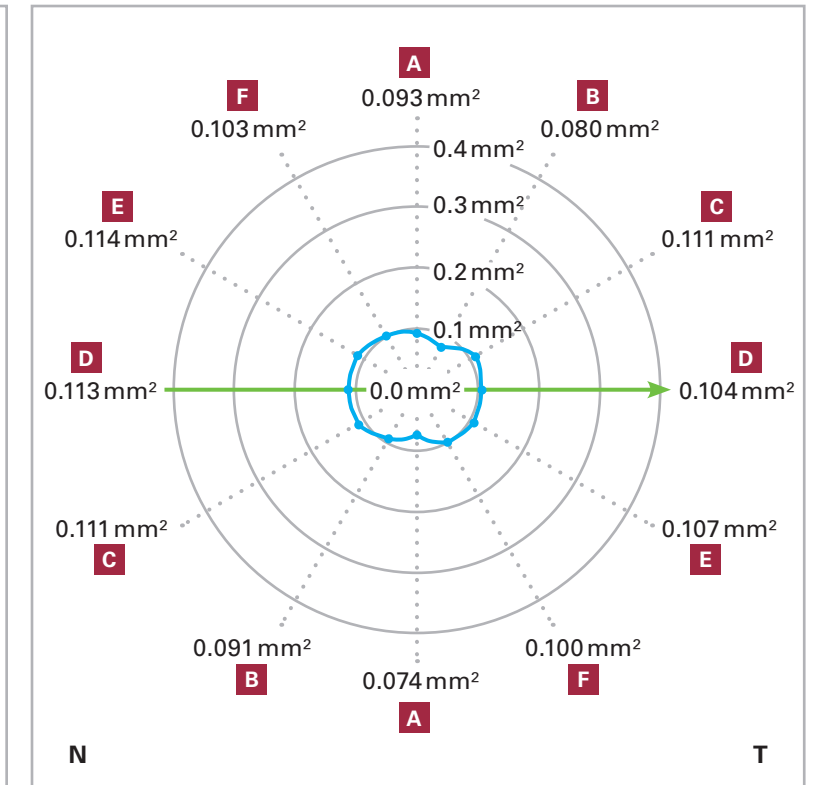


Anterior segment parameters at a glance

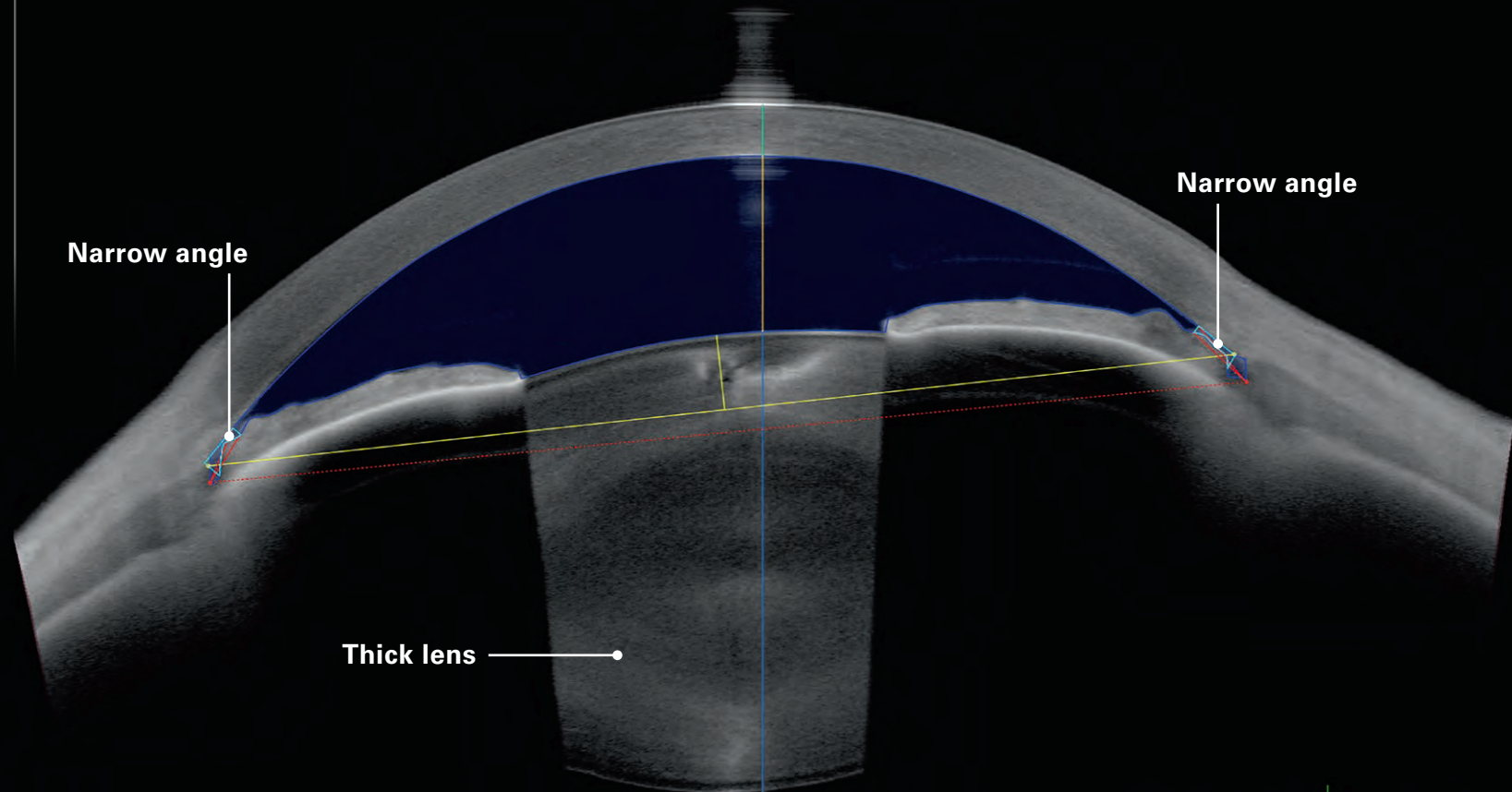
ACA 500



TISA 500



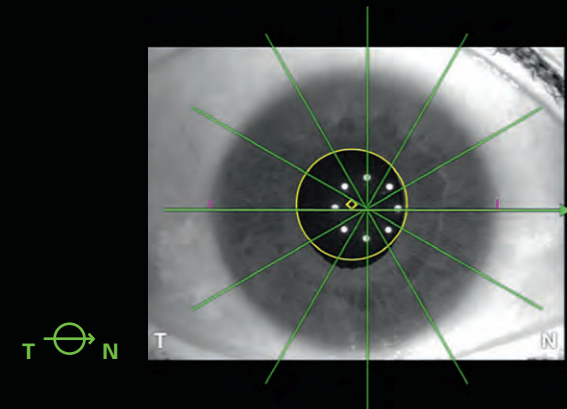
Benefit from anterior segment parameters at a glance using the 360° graphs to optimize your daily clinical routine. The Metrics App features the essential anterior chamber metrics such as aqueous depth, anterior chamber angles (ACA), angle opening distance (AOD), scleral spur angle (SSA), trabecular iris space area (TISA), ACA distance, spur-to-spur distance, central corneal thickness, and white-to-white.




200 μm

Narrow anterior chamber angles and thick lens

Image courtesy: Ulrich Kellner, MD, Siegburg, Germany



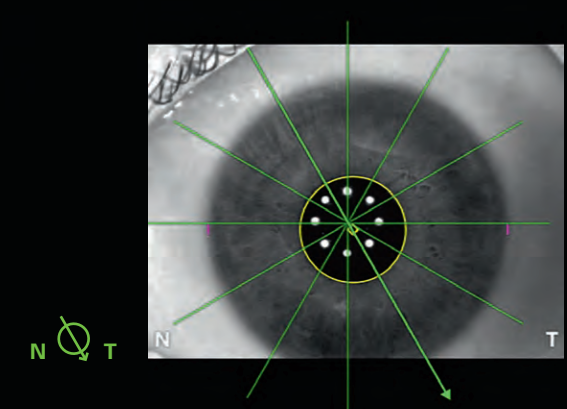
T N



200 μm

Open anterior chamber angles

Image courtesy: Ulrich Kellner, MD, Siegburg, Germany



N T



Headquarters

Heidelberg Engineering GmbH · Max-Jarecki-Str. 8 · 69115 Heidelberg · Germany
Tel. +49 6221 64630 · Fax +49 6221 646362

AUS

Heidelberg Engineering Pty Ltd · Suite E5, 63 - 85 Turner St · Port Melbourne VIC 3207
Tel. +61 396 392 125 · Fax +61 396 392 127

CH

Heidelberg Engineering GmbH · Schulstrasse 161 · 8105 Regensdorf
Tel. +41 44 8887 020 · Fax +41 44 8887 024

FIN

Heidelberg Engineering GmbH · Luomannotko 6 · 02200 Espoo
Tel. +358 505 226 963

UK

Heidelberg Engineering Ltd. · 55 Marlowes · Hemel Hempstead · Hertfordshire HP1 1LE
Tel. +44 1442 502 330 · Fax +44 1442 242 386

www.HeidelbergEngineering.com

200468-001 INT/AE19 © Heidelberg Engineering GmbH